

RADIOLOGY ROUNDS

MARTIN QUAN, MD

Department Editor

A young woman with severe lung disease

James D. Collins, MD

This 17-year-old girl came to a family medicine clinic in the southern San Joaquin Valley of California with a history of progressive dyspnea on exertion and orthopnea accompanied by fever, chills, pleuritic chest pain, weight loss, and general debilitation. A single posteroanterior (PA) chest radiograph displayed bilateral diffuse amorphous densities throughout both lungs, primarily the left; bilateral thickened bronchi and air bronchograms (radiographic densities of air-filled bronchi running through the airless lung); and rounded hunched-up shoulders, right higher than the left, suggesting laxity of the sling/erector muscles (trapezius, levator scapulae, serratus anterior) of the shoulder.¹ Soft tissue and cardiomeastinal structures were normal (Figure 1).

The diagnosis was disseminated coccidioidomycosis, and she was treated conservatively with antifungal agents. She continued to complain of shortness of breath, fever, chills, and chest pain. Since she had clinical ascites and was not responding to conservative care, she was transferred 3 months later to a medical center in Los Angeles where further chest radiographs were obtained.

The PA chest radiograph (Figure 2, page 18), which was compared with the earlier one, displayed clearing of the diffuse hazy densities; cavitations over the posterior left 5th and 6th ribs; prominent pulmonary vascularity; increased heart size suggesting diffuse chamber enlargement or pericardial effusion; blunting of the right and left costophrenic sulci with pleural thickening on the left suggesting bilateral pleural effusions²; and bulging of both flanks reflecting ascites.

The lateral chest radiograph (Figure 3, page 18) displayed a narrow thorax; left ventricular enlargement displaced against the spine, and increased abdominal girth.

Dr. Collins is professor, department of radiology, David Geffen School of Medicine at UCLA. Dr. Quan is professor of family medicine, department of family medicine, David Geffen School of Medicine at UCLA. He is also editor in chief of *Family Practice Recertification*.

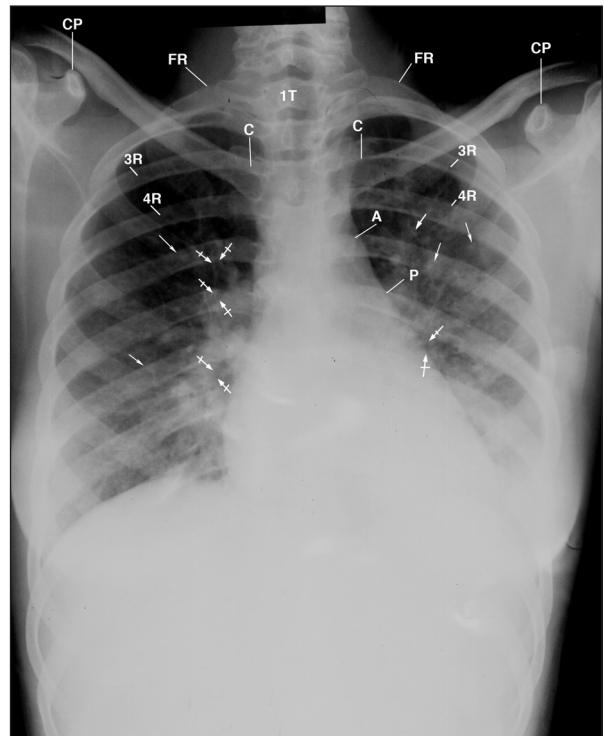


Figure 1 This posteroanterior chest radiograph displays multiple amorphous nodular densities (arrows) in both lungs; anterior rotated clavicles over the posterior third intercostal spaces (between the posterior third and fourth ribs), hazy amorphous density in the left lung obscuring the left hemidiaphragm and the adjacent heart margin, reflecting a large pleural effusion, and air bronchograms (bar arrows). Observe the hunched-up, rounded shoulders, with the right higher than left suggesting laxity of the sling/erector muscles (trapezius, levator scapulae, serratus anterior) of the shoulder.

Key: A = aorta; C = clavicle, CP = coracoid process; P = pulmonary artery; 3R and 4R = posterior third rib and posterior fourth rib; 1T = first thoracic vertebra.

She also complained of left wrist pain, and radiographs of her left wrist were obtained. They displayed a lucent defect in the ulna styloid, cortical disruption, extension into the styloid process, and soft tissue swelling (Figure 4, page 20).

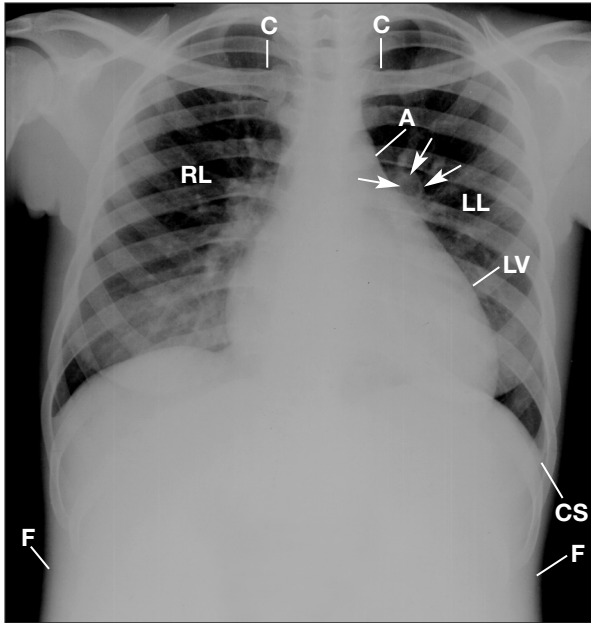


Figure 2 This posteroanterior chest radiograph, compared with Figure 1 (page 17), displays some clearing of diffuse hazy densities; cavitations above the posterior left sixth intercostal space (arrows); prominent pulmonary vascularity; an enlarged left ventricle, suggesting diffuse chamber enlargement or pericardial effusion; blunting of the right and left costophrenic sulci; pleural thickening adjacent to the left costophrenic sulcus, suggesting bilateral pleural effusions, and bulging of the flanks, reflecting ascites.

Key: A = aorta; C = clavicle; CS = costophrenic sulcus; F = flank; LL = left lung; LV = left ventricle; RL = right lung.

Subsequent chest radiographs, both PA and lateral, confirmed the patient's worsening condition: increased heart size, sharp margination of the vascular structures in the upper lungs, continued suspicious cavitations in the left lung adjacent to the left pericardium, bulging flanks, pleural thickening adjacent to the left costophrenic sulcus, and expanded abdominal girth from ascites. Similarly, follow-up wrist radiographs displayed advanced destruction of the distal ulna and styloid process and further cortical breakdown with increased soft tissue swelling.

The burden of coccidioidal disease

Coccidioidomycosis (Valley fever) is primarily a disease of the lungs caused by inhaling the spores of *Coccidioides immitis*. It is endemic to the southwestern United States and northwestern Mexico in dry,

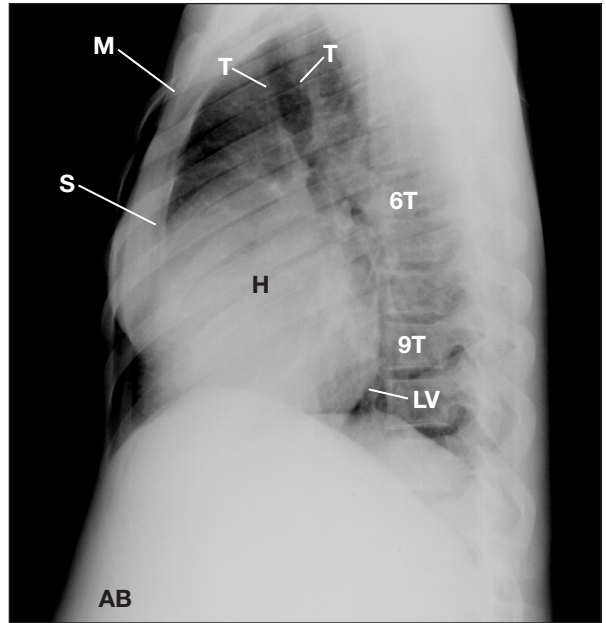


Figure 3 This lateral chest radiograph displays a narrow thorax; left ventricular enlargement displaced against the thoracic vertebra; and increased abdominal protuberance, reflecting ascites. Observe the depressed manubrium and body of the sternum reflecting mild pectus excavatum.

Key: AB = abdomen; H = heart; LV = left ventricle; M = manubrium; S = sternum; T = trachea; 6T = sixth thoracic vertebra; 9T = ninth thoracic vertebra.

hot, dusty areas, particularly in the San Joaquin Valley of California and southern Arizona, where the spores exist in the alkaline soil.^{3,4} They may become airborne by disturbances of the soil such as winds (particularly dust storms), earthquakes, construction, farming, and archaeological digs and can also be carried by fomites. During the 1950s, private vehicles belonging to military personnel stationed in California were transported to Germany. Sand containing spores of *C immitis* in the wheel wells of these vehicles caused a local outbreak of coccidioidomycosis (personal experience).

Coccidioidomycosis is symptomatic in only about 40% of cases, but a travel history is important in patients who present with the more debilitating symptoms of protracted cough, fatigue, fever, chills, weight loss, and chest pain.³ Although the disease is usually self-limited, a small percentage of cases may become disseminated with potentially serious complications. Some population groups are at higher risk for dissemination: dark-skinned people (African-Americans, Mexican-Americans, Asians [particularly Filipinos],

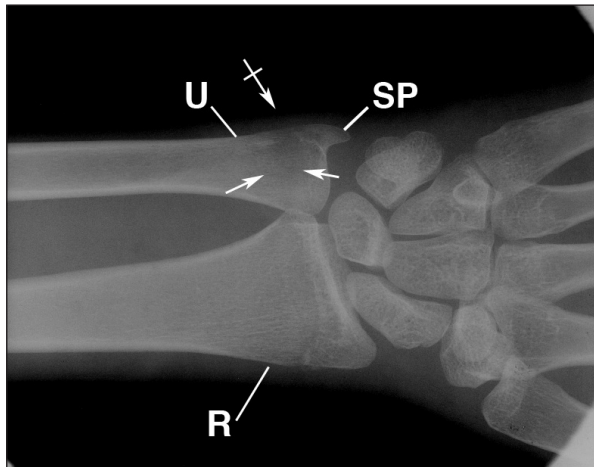


Figure 4 This anteroposterior wrist radiograph displays advanced lytic destruction of the distal ulna (arrows), the styloid process, and further cortical breakdown with increased soft tissue swelling (bar arrow).

Key: R = radius, SP = styloid process, U = ulna.

and Native Americans), women in the last trimester of pregnancy, and patients who are immunocompromised (HIV/AIDS, transplant, diabetes) or taking immunosuppressive medications. The usual sites of extrapulmonary involvement are the skin, reticulo-endothelial system (especially the liver and spleen), meninges, joints, and bones.

The bony lesions are usually low grade, lytic lesions of cancellous bones that display little or no tendency to produce reactive sclerosis or periostitis. They may be associated with osteocutaneous fistulous tracts and are especially suggestive of coccidioidomycosis when found at bony prominences such as patellar edges; the acromial, coracoid, ulnar, or radial processes, as solitary lesions at rib margins, as localized destruction of the outer table of the skull, or in the vertebral body, arch, or processes.^{5,6}

Long-term antifungal medications that are used for treatment include ketoconazole (Nizoral), itraconazole (Sporanox), and fluconazole (Diflucan) in chronic, mild-to-moderate disease, and amphotericin B, given intravenously or inserted into the spinal fluid, for rapidly progressive disease.^{7,8}

The lumbar spine and lower extremity radiographs were negative in this patient who had widely disseminated disease with massive hepatosplenomegaly, ascites, meningitis, and cutaneous lesions. Cultures of

the skin lesions, bone marrow, and periapical tooth abscess all grew *C immitis*. The ulnar lesion was typical for coccidioidal bone involvement. Cardiomegaly in this patient may have been due to a cardiomyopathy caused by *C immitis* or may have been a pericardial effusion secondary to *C immitis* infection. Interestingly, although she was desperately ill with widespread coccidioidomycosis, her lung findings were generally not as severe as might have been expected. She died 2 years after the events described here. An autopsy was not performed.

Take-home messages from this case

Coccidioidomycosis is endemic to hot, dry, dusty areas of the southwestern United States and northwestern Mexico. It is usually self-limited but a small percentage of cases may become disseminated with associated serious complications that can affect bone, skin, and meninges. Groups most likely to develop disseminated disease include nonwhite persons (especially African-Americans, Asians (especially Filipinos), Mexican-Americans, Native Americans, and Asians) and those who are immunocompromised or taking immunosuppressive medications. If a patient has traveled through regions endemic for coccidioidomycosis and develops a cold, fever, and cough, think possible coccidioidomycosis—a travel history is important. ■

REFERENCES

- Woodburne RT, Burkel WE. Essentials of Human Anatomy. 8th ed. New York: Oxford University Press; 1988.
- Collins JD, Burwell D, Furmanski S, et al. Minimal detectable pleural effusions: A roentgen pathology model. *Radiology* 1972;105:51-53.
- Bennett JE. Coccidioidomycosis. In: Kasper DL, Braunwald E, Fauci AS, et al, eds. *Harrison's Principles of Internal Medicine*. 16th ed. New York, NY: McGraw Hill; 2005:1180-1182.
- Galgiani JN. Coccidioidomycosis: A regional disease of national importance. Rethinking approaches for control. *Ann Intern Med* 1999;130:293-300.
- Pugh DG. The roentgenologic diagnosis of diseases of bones. In: Robbins LL, ed. *Golden's Diagnostic Roentgenology*. Vol 2. Philadelphia, Pa: Williams & Wilkins; 1961;514-515.
- Collins JD, Bassett L, Main GD, et al. Percutaneous biopsy following positive bone scans. *Radiology* 1979;132:439-442.
- Galgiani JN, Ampel NM, Catanzaro A, et al. Practice guidelines for the treatment of coccidioidomycosis. *Clin Infect Dis* 2000;30:658-661.
- Valley Fever Center for Excellence. Valley fever. Reprinted from University of Arizona's Valley Fever Center for Excellence. May 2003. Available at: <http://www.projinf.org/fs/vfever.html>. Accessed January 20, 2006.