

RADIOLOGY ROUNDS

MARTIN QUAN, MD

Department Editor

A man with a cough who couldn't sleep on his left side

James D. Collins, MD

This 40-year-old white male construction worker was referred to our university medical center to rule out lung cancer. He had seen his family physician 4 months before for an upper respiratory infection. His symptoms included cough, fever, night sweats, and a temperature of 102°F. He was treated with antibiotics, and the acute illness resolved, but a nonproductive cough continued. When we saw him, his blood pressure was 150/90 mm Hg; pulse rate, 80; and respiration, 17-18 breaths per minute. He said the cough was exacerbated by lying on his left side and relieved by lying on his right side, the only position in which he could sleep. He had no hemoptysis, pleuritic pain, or history of tuberculosis. He said he lost about 10-15 lb over the 4-month period. A single posteroanterior (PA) chest radiograph revealed a left lung mass, which prompted his referral to our center.

On admission, pertinent findings of his physical examination were diminished breath sounds and wheezing at the left lung base. A routine laboratory workup detected proteinuria (2+ to 4+)

Radiologic findings

A PA chest radiograph displayed a large, sharply marginated mass extending from the trifurcation of the left mainstem bronchus (Figure 1). The mass obscured the left cardiac margin and shifted pulmonary blood flow into the right pulmonary artery. Other observations included an unevenly elevated left hemidiaphragm secondary to atelectasis from the mass lesion, a shallow left costophrenic angle that might indicate a small pleural effusion, concavity on the right margin of the trachea suggesting increased aeration of the right lung, decreased blood flow on the left side, and near absence of air beyond the left mainstem bronchus.

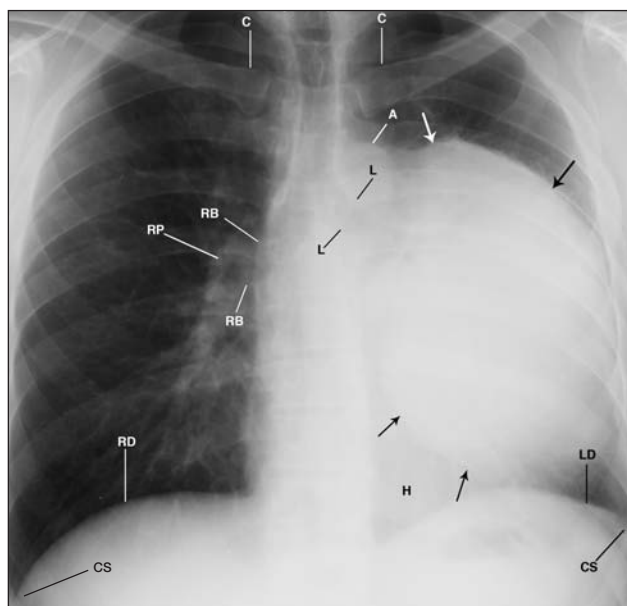


Figure 1 A large mass extends from the hilum of the left mainstem bronchus (L) over the heart (H) into the inner aspect of the left ribs. The margins (arrows) are well defined without pseudopod-like extensions. The shallow left costophrenic sulcus (CS) denotes the uneven elevation of the left hemidiaphragm. Observe the right concave margin of the trachea (T) reflecting diminished aeration of the left lung. A = aorta; C = clavicle; H = heart; LD = left hemidiaphragm; RB = right mainstem bronchi; RD = right hemidiaphragm; RP = right pulmonary artery.

A negative image of the same radiograph (Figure 2, page 00) displayed a lucent zone (not air) in the left upper lobe bronchus between the mass and the aorta and next to the mass a narrowing of the left intercostal spaces compared with the right.

Diagnosis

The differential diagnosis must include tumor, cyst, and possibly an aortic aneurysm, with tumor being the most likely. A left pneumonectomy was performed, and the pathology report on biopsy specimens of the lesion said it was composed of monoclonal plasma cells. The tumor did not invade any blood vessels or

Dr. Collins is professor, department of radiology, David Geffen School of Medicine at UCLA. Dr. Quan is professor of family medicine, department of family medicine, David Geffen School of Medicine at UCLA. He is also editor in chief of *Family Practice Recertification*.

bronchi but did surround and compress them. There was no evidence of lymph node involvement.

Discussion

Plasmacytomas, or plasmomas, are plasma cell neoplasms and part of the disease group that includes solitary myeloma, multiple myeloma, and plasma cell leukemia. All are variations of the same disease—single or multiple neoplasms of plasma cells from within the bone marrow that disseminate tumor cells into the blood. From the hematologist's point of view, it is a subleukemic or an aleukemic state with 1%-5% plasma cells in the peripheral blood.

Plasmacytomas, which can be further classified as solitary plasmacytomas of bone or extramedullary plasmacytomas (EMPs) of soft tissue, are rare and most often occur in the upper respiratory tract (some authors say upper aerodigestive tract), including the oral cavity and paranasal sinuses. A plasmacytoma of the lung is extremely rare. In a review that covered most of the 20th century, EMPs accounted for 4% of all plasma cell tumors. Of these, 714 cases (82%) were found in the upper aerodigestive tract and 155 (18%) elsewhere in the body.¹ A recent discussion of pulmonary plasmacytoma cited only 44 cases in the literature.²

Diagnostic characteristics of pulmonary EMP include the following: no sign of myeloma, minimal proteinuria, no Bence Jones proteinuria, and no lymph node or bony involvement. To differentiate EMP from myeloma, evaluation of serum and urine electrophoresis for monoclonal (M) protein, bone scan, and skeletal radiographs should be done. Serum M protein may in fact be found in about 25% of patients, but it generally disappears after treatment. EMPs are highly sensitive to radiotherapy and respond well to resection, which is often the initial therapeutic approach in areas other than the head or neck. Combined therapy may be recommended if lymph nodes are involved. Rates of progression and disease-free survival are 70%-85% at 10-14 years.³ Only a minority of EMPs progress to myeloma.

In this patient, results of diagnostic testing (Bence Jones protein, serum electrophoresis, and bone scan and survey) were all negative, producing no evidence of myeloma and suggesting this was a true plasmacytoma. An initial urinary protein level of 9.5 g per 24 hours dropped to 0.8 g on the day after surgery and

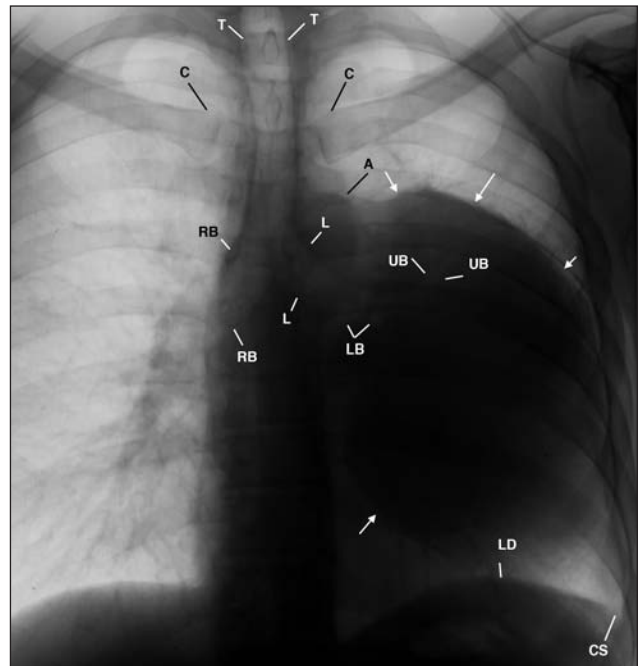


Figure 2 This negative image of Figure 1 (page 00) provides a different perspective to the disease in the left lung. Observe the mass (arrows), elevated left mainstem bronchus (LM), sharp cutoff of air in the compressed lower lobe bronchus (LB), and air in the upper lobe bronchus (UB). A = aorta; CS = costophrenic sulcus; LD = left hemidiaphragm; RM = right mainstem bronchus; T = trachea.

was 0.2 gm at discharge. He was alive 5 years later, but lost to follow-up thereafter.

Take-home message

The important clue to this patient's disease was that he could sleep only when he was lying on his right side, which increased blood supply and ventilation to his compromised left lung. The chest radiographs displaying the diminished blood flow facilitated the diagnostic process and led to the pathology report that identified the plasma cells in the mass lesion. ■

REFERENCES

- Alexiou C, Kau RJ, Dietzfelbinger H, et al. Extramedullary plasmacytoma. Tumor occurrence and therapeutic concepts. *Cancer* 1999;85:2305-2314.
- Wise JN, Schaefer RF, Read RC. Primary pulmonary plasmacytoma. A case report. *Chest* 2001;120:1405-1407.
- Multiple myeloma and other plasma cell neoplasms. PDQ: Treatment. Extramedullary plasmacytoma. National Cancer Institute. Available at: <http://www.cancer.gov/cancertopics/pdq/treatment/myeloma/HealthProfessional/page 7>. Accessed June 6, 2007.