

Filariasis and Traumatic Chyluria as Displayed by Lymphangiography

James D. Collins, MD

Keywords: radiology ■ imaging ■ anatomy ■ filariasis ■ chyluria ■ lymphangiogram

J Natl Med Assoc. 2011;103:445-449

Author Affiliations: University of California at Los Angeles, Department of Radiological Sciences, Los Angeles, California.

Correspondence: James D. Collins, MD, University of California at Los Angeles, Department of Radiological Sciences, 10833 Le Conte Ave, BL-428 CHS/UCLA mail code 172115, Los Angeles, CA 90095 (jamesc@mednet.ucla.edu).

INTRODUCTION

Chyluria is the presence of chyle in the urine, giving it a milky appearance.^{1,2} Chyle is the milky fluid taken up by the lacteals from the food in the intestine after digestion. It consists of lymph and emulsified fat that passes into the thoracic duct and subclavian veins. When there is extravasation of chyle into the thorax, it is called chylothorax and in the abdomen, chylous ascites. Chyluria is most often caused by filarial parasites (*Wuchereria bancrofti*), aortoiliac grafting, and trauma. Bipodal lymphangiography of the foot/hand is the radiologic special procedure where Ethiodol contrast is injected into the dorsal lymphatics to visualize flow to and from lymph nodes. It is used as a diagnostic as well as therapeutic procedure.¹ Fluoroscopic control allows extravasation and circumvention of the Ethiodol into the abnormal communication of lymphatics into the pelvis, kidney, and/or bladder. Surgical correction may consist of tying off the thoracic duct and/or embolization. If not corrected, the patient develops protein-losing enteropathy. Two patients with chyluria were selected for this presentation with filariasis and traumatic chyluria (football injury to the abdomen). The traumatic chyluria displayed considerable loss of weight and was not corrected at surgery.

The lymphatic vascular system develops at the end of the fifth week. This is about 2 weeks later than the development of the cardiovascular system. The current view is that the earliest lymph vessels arise as capillary offshoots of the endothelium of veins.²

The development of the pulmonary lymphatics parallel veins and appear at the hilum in the 6th to 7th week, and by the end of the 10th week they are found in the

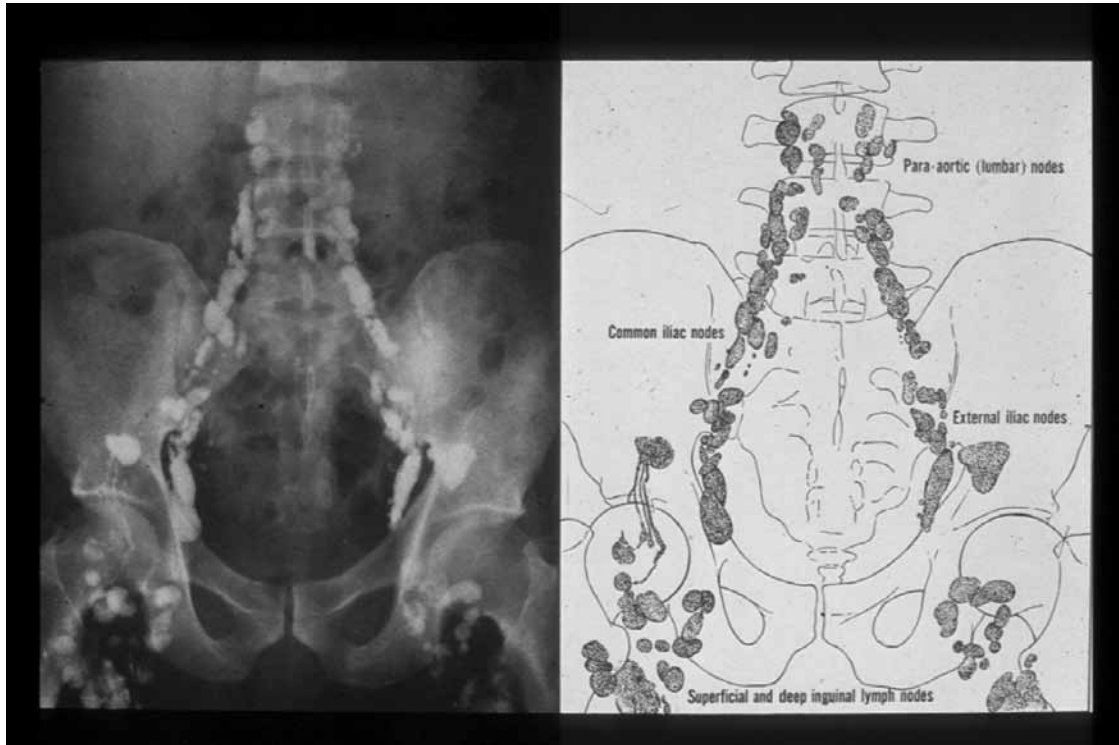
lung. Therefore, by the end of the 18th to 20th week, they are well developed in the lung and the separate distinct pulmonary lobules. Historically, lymphatics were first recognized in 300 BC by Herophilus. They were rediscovered some 2000 years later by Aselli in 1622. Bartholin coined the term *lymphatics* in 1653, and Rudbeck in that same year described pulmonary lymphatics. Pulmonary lymphatic bicuspid valves were first discussed in 1675. In 1952, the first lymphangiogram was performed by Kinnot. This was first accomplished by identifying the lymphatics with blue dye for accurate placement.³ The senior author has performed this procedure for more than 40 years as a routine diagnostic procedure.

The purpose of this presentation was to demonstrate how the procedure is used in teaching anatomy of the lymphatic system to anatomists, medical students, and other health professionals and to localize sites of lymphatic extravasation. The plain x-ray films, normal lymphatics, and lymph nodes (Figures 1 and 2) are displayed within the pelvis and abdomen, fistulous communication within the right kidney—filariasis (Figure 3) (*Wuchereria bancrofti*), and traumatic fistulous communications within the left kidney (Figure 4).

METHODS AND MATERIALS

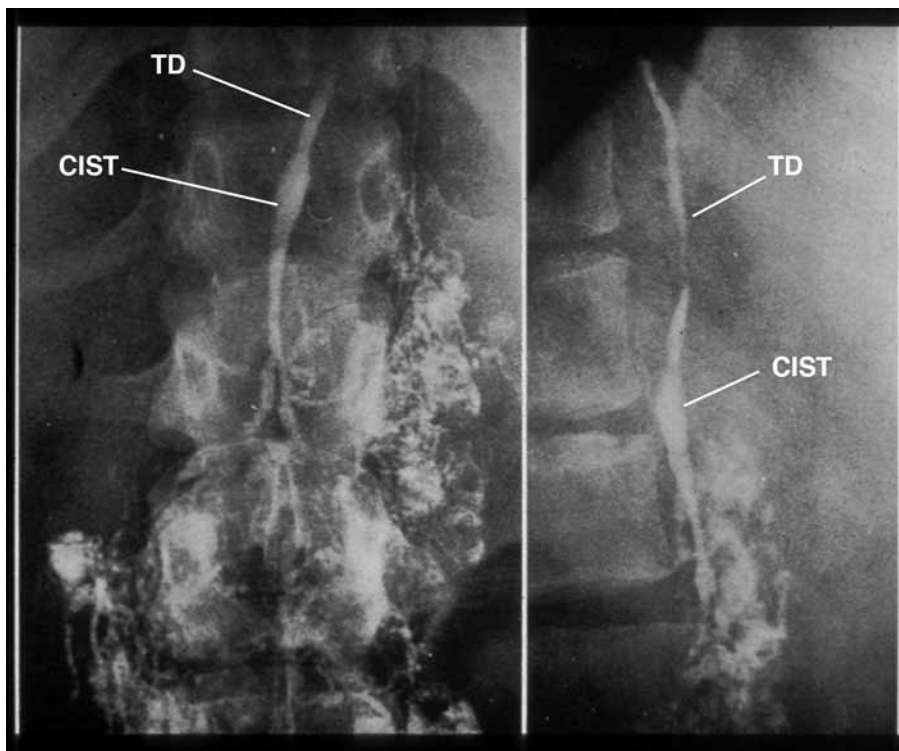
The patient is informed of how the procedure is performed, the length of the procedure, and reasons for the procedure. The complications and risks of the procedure and postoperative wound care are also discussed. The contrast material may remain in the lymph nodes for 3 months to 6 years. The patient should have nothing by mouth as of midnight prior to the procedure. The patient is prepped and draped in routine sterile fashion. A 1:1 solution of methylene blue and 1% xylocaine is injected into the first interspace of the foot (second interspace of the hand). The blue dye injection may come before or after draping. The local anesthetic (2-3 cc) is injected over the dorsum of the foot interspace (over the dorsum of the hand between second and third digits, proximal to the interspace) to separate fascial planes. A superficial skin incision is made horizontally, and blunt dissection is carried down to the subcutaneous tissues. At this point, a gentle massage of the skin proximal

Figure 1. Anterior-Posterior Abdomen Post Bilateral Delayed Ethiodol Injection



The unlabeled and labeled normal superficial, deep inguinal, common, and external iliac, para-aortic (lumbar) lymph nodes.

Figure 2. Cisternal Chyli (CIST) and Thoracic Lymph Duct (TD)



Normal structures as above.

to the incision forces the methylene blue to dilate the lymphatic channels. The channels are selectively stripped of their fascia and connective tissue for needle insertion. Forceps are then placed gently beneath the lymphatic channel to be cannulated and tension is applied. The needle is then introduced at a 45° angle to allow the tip to enter the lymphatic channel. At this point, the fluid to be injected (contrast agent or normal saline) is connected to the syringe by the k-50 tubing and can be used as a stream to aid in the dilation of the lymphatic as the needle is inserted into the lumen. Once this is accomplished, a single silk ligature and an adhesive bandage are used to secure the needle. The contrast within the syringe is connected to a continuous pressure pump with a pressure of 0.2 to 0.6 kg/cm². A saline soaked gauze is placed over the wound to maintain moisture. The injection time of contrast material delivery depends on the patient's anatomy and clinical stage of disease. The injection time may vary from 20 to 45 minutes. Both extremities should be injected for a complete study. Upon completion of the injection, routine radiographs are obtained. A delayed 24- to 48-hour series of radiographs are also obtained. Instructions are given for wound care and pain. The physician should be contacted if there are any complications, such as unusual rashes and itching.

CASE 1

The first patient was known to have chyluria secondary to filariasis. She came from India to have the procedure performed and was lost to follow-up after the procedure (Figure 3).

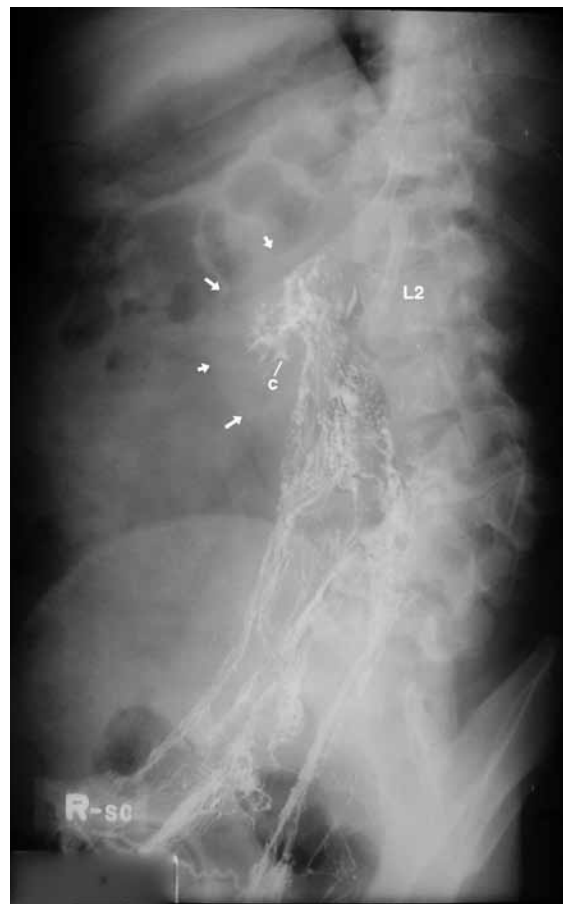CASE 2

This 40-year-old right-handed male presented with weight loss and chronic chyluria (Figure 4). He had suffered blunt trauma from a football injury to his abdomen many years before, for which he was hospitalized. He had multiple diagnostic procedures. An outside bipedal lymphangiogram displayed periaortic lymphatic circumvention of the left renal pelvis (not available for my review). Lying supine at rest stopped the flow of chyle. However, simple exercises restarted flow. He was concerned about his weight loss. Under cystoscopy of his bladder revealed large "clots of chyle" Because of the above findings, bipedal lymphography was requested to best display the lymphatic fistulous communication within the left kidney. Routine initial plain radiographs of the chest, abdomen, and pelvis were obtained (Figures 5 and 6). A No. 30-gauge lymphangiogram needle was successfully introduced displaying the dorsal subcutaneous lymphatic over both feet without difficulty. A screw drive pump was used for the injection of Ethiodol. Contrast (20 cc) was used for the procedure, monitored under fluoroscopic control into normal lymphatics within the thigh, superficial inguinal lymphatics,

femoral, iliac, hypogastric, and the periaortic divisions up to the third lumbar vertebrae bilaterally (Figure 7). Ethiodol circumvented the dilated left renal pelvis, capsular lymphatics, and the dilated left and right thoracic lymph ducts over the 12th thoracic vertebrae—also the renal pelvis, adrenal, and capsular lymphatics of the left kidney at 12:32 hours as above.

Overhead radiographs confirmed the initial flow of contrast within the pelvis, abdomen, and the thorax, renal pelvis, adrenal, and capsular lymphatics of the left kidney at 12:32 hours as above (Figure 4).³ Overhead radiographs confirmed the initial flow of contrast within the pelvis, abdomen, and the thorax (Figure 7). The left posterior oblique radiograph of the abdomen best displayed dilated left pelvic lymphatics communicating with smaller lymphatics marginating the left adrenal gland and the renal capsule (Figure 4). The left posterior oblique radiograph confirmed the absence of Ethiodol within the right renal pelvis. Amorphous dense blood vessels of the right lung marginated the right lung

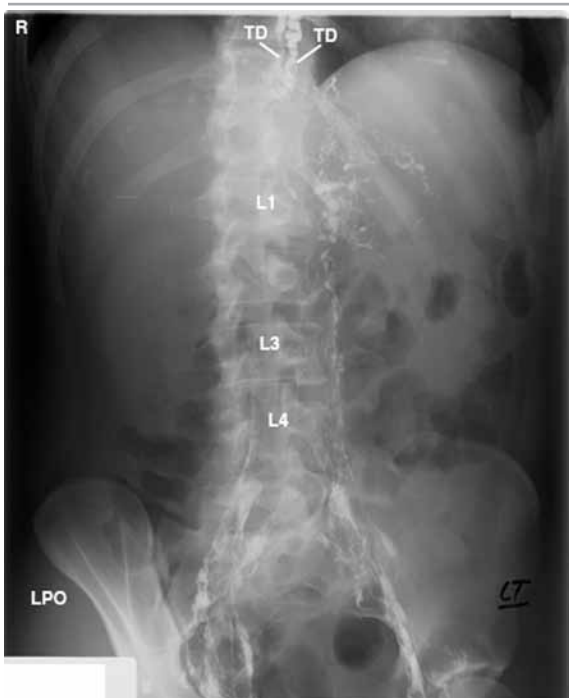Figure 3. Right Posterior Oblique Abdomen Post Lymphangiogram



The diversion of Ethiodol from the right (R) kidney (arrows) into the draining lymphatics inferiorly down into the direction of the bladder post filariasis in a female from India.

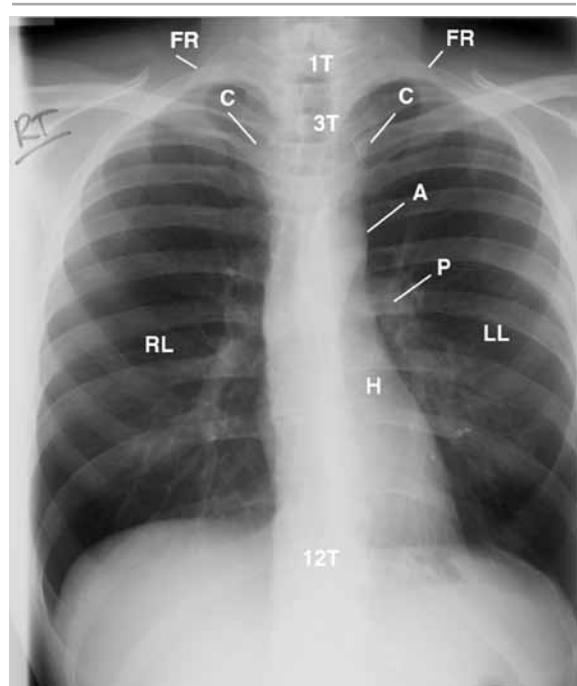
C, minor calyces; L2, second lumbar vertebra.

Figure 4. Left Posterior Oblique Abdomen Post Bilateral Ethiodol Injection



Paralumbar extravasations of Ethiodol into dilated capsule lymphatics of the left kidney; dilated proximal left ureter (not labeled), and the dilated right and left thoracic lymph ducts (TD) reflecting impedance to lymphatic return.
L1, L3, L4, Lumbar vertebrae; R, right.

Figure 5. Posterior-Anterior Chest Radiograph of Posttraumatic Injury to the Pelvis



Observe the anterior-rotated heads of the clavicles (C) low over the third ribs; thin narrow margins of the heart (H) accentuating hyperaerated lungs.

A, aorta; FR, first rib; LL, left lung; 1T, first thoracic vertebra; P, pulmonary artery; RL, right lung; 3T, third thoracic vertebra; 12T, 12th thoracic vertebra.

base-to the right of the 11th and 12th thoracic vertebrae (not labeled). The delayed posteroanterior and lateral chest radiographs displayed Ethiodol within dilated lymphatics over the left renal pelvis and capsule into the thoracic lymph ducts up to the level of the eighth thoracic vertebra, with left concave kyphoscoliosis of the thoracic spine.⁴ On completion of the study, the patient was instructed not to immerse his feet in water and/or to shower to prevent possible infection of the cut-down over his feet. Follow-up radiographs revealed excellent visualization of normal lymph nodes within the femoral, inguinal, iliac, hypogastric, and lower periaortic divisions (not displayed). Contrast was not displayed over the right kidney. The posteroanterior and lateral chest radiographs (not displayed) confirmed left concave kyphoscoliosis of the thoracic spine, degenerative anterior wedging of seventh and eighth thoracic vertebrae above described, thin subcutaneous tissues, and residual contrast within a single lymph node anterior to the 12th thoracic vertebra. No extravasation of contrast was identified within the thorax and/or in the region of the left/right thoracic lymph ducts at the region of the left/right subclavian and internal jugular veins.

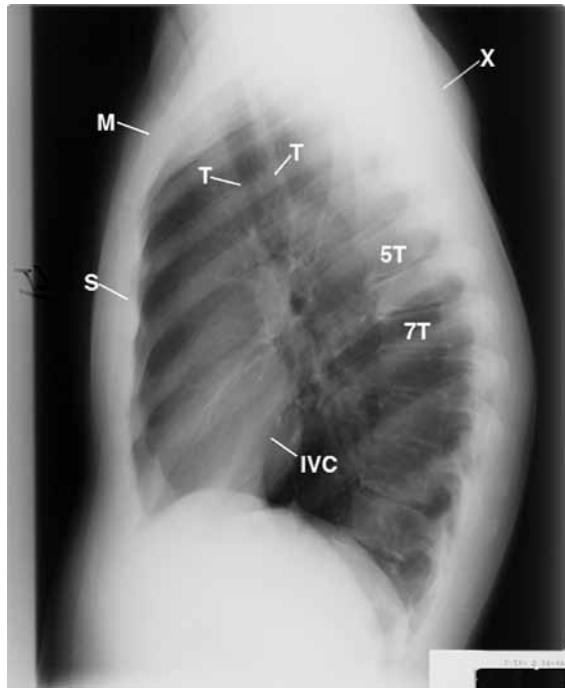
COMMENT

The 24-hour follow-up lymphangiogram images displayed the site of contrast extravasation to the left of L1-2 of the lumbar spine and contrast into the thoracic ducts. Fluoroscopic spot film radiographs documented the site of extravasation as above described. The initial and delayed radiographs (digitized and analog) confirmed extravasation of contrast to the left of L1-2 into the left renal bed marginating the kidney and the adjacent soft tissues.

CONCLUSION

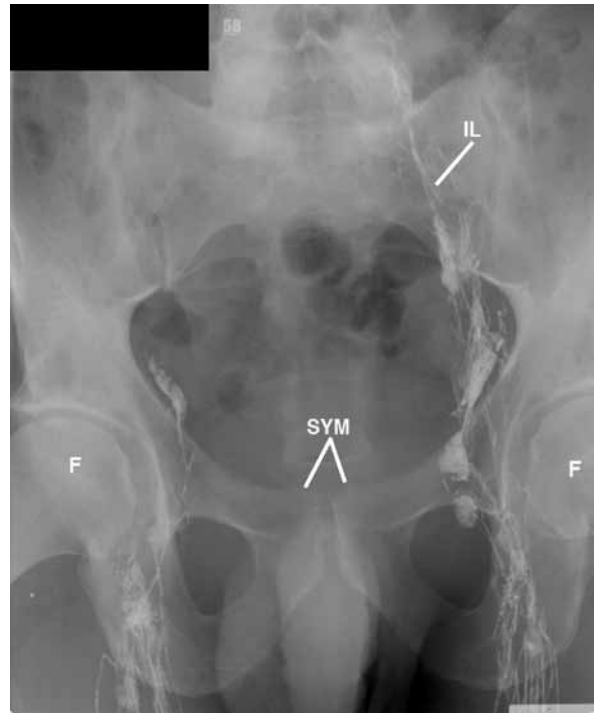
- Postresection of the lymphatics increasing left renal chyluria,
- Protein-losing enteropathy secondary to number 1,
- Dilated left and right thoracic lymph ducts reflecting impedance to lymph drainage into the junction of the internal jugular and subclavian veins,
- Extravasation of Ethiodol at the left of L1-2 into the left renal bed and soft tissues,
- Left concave thoracic spine kyphoscoliosis,
- Degenerative anterior wedging of the seventh and eighth thoracic vertebrae,
- Bilateral round shoulders.

Figure 6. Lateral Chest Radiograph



Displays the forward shift of the cervicothoracic spine, increasing the slope of the first ribs backwardly displaying the manubrium (M); rounding of the shoulders (X), and degenerative changes of the anterior thoracic vertebrae (5T-7T) accentuating kyphosis of the thoracic spine. IVC, inferior vena cava; S, sternum; T, trachea.

Figure 7. Anterior-Posterior Pelvis Post Ethiodol Injection on the Left While Injecting Ethiodol on the Right



Femur (F), Right common iliac lymph node with afferent and efferent lymphatics (IL), Symphysis pubis (SYM).

TAKE-HOME MESSAGE

Unlike previous radiology rounds, the diagnosis is presented before the clinical history. Basically, the lymph system returns carbon to the liver for protein synthesis. When the lymph system is interrupted, protein losing enteropathy, weight loss, anemia, and edema occurs. The 2 cases above describe parasitic and traumatic etiologies that cause chyluria, resulting in protein-losing enteropathy. It is important for health professionals and physicians to know the anatomy of the lymph system and the resulting physiological events that occur when the lymph system is obstructed. A lymphangiogram is the only procedure that displays the lymph system on plain films and monitored fluoroscopic control.

ACKNOWLEDGMENTS

Thanks to Portia Daniels and Steven Do.

REFERENCES

1. Collins JD, Saxton E, Miller TQ, Ahn S, Carnes A, Smith R. Traumatic chyluria as displayed by lymphangiogram. *Faseb J.* 2011;25:681-683.
2. Saab S, Nguyen S, Collins JD, Kunder G, Busuttill R. Lymphedema Tarda After Liver Transplantation: A Case Report and Review of the Literature *Experimental Clinical Transplant.* 2006;4:567-570.
3. Collins JD, Shaver M, Disher A, Batra P, Brown K, Miller TQ. Imaging the Thoracic Lymphatics: Experimental Studies of Swine. *Clin Anat.* 1991;4:433-446.
4. Collins JD. Missed Diagnosis in a Woman With Past Malignancy. *J Natl Med Assoc.* 2010;102:433-436.
5. Collins JD. www.tosinfo.com. Accessed April 2011. ■